

EP CASE REPORT

Transvenous biventricular pacing in double-inlet left ventricle following ventricular septation and atrioventricular valve replacement

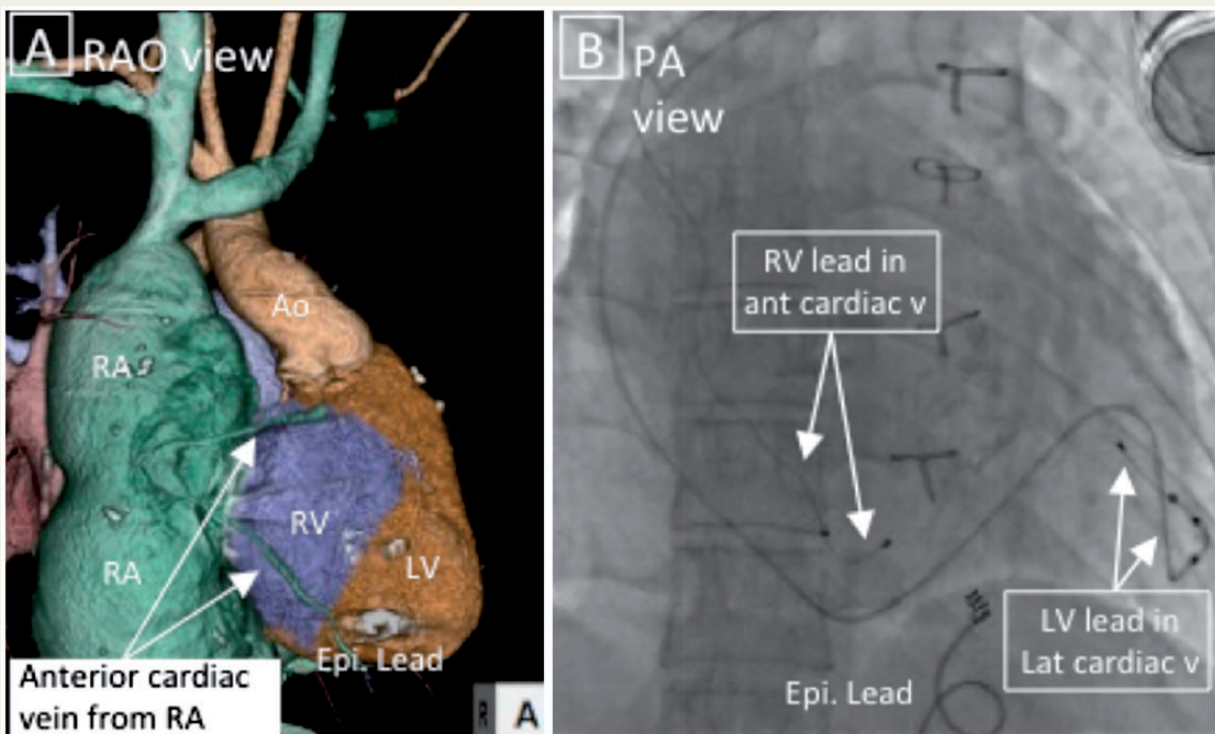
Daiji Takeuchi¹, Daigo Yagishita², Keiko Toyohara¹, Tomomi Nishimura¹, In-sam Park¹, and Morio Shoda^{2*}

¹Department of Paediatric Cardiology, Tokyo Women's Medical University, 8-1 Kawada-cho, Shinjuku-ku, Tokyo, 162-8666 Japan; and ²Department of Cardiology, Tokyo Women's Medical University, 8-1 Kawada-cho, Shinjuku-ku, Tokyo, 162-8666 Japan

* Corresponding author. Tel: +81-3-3353-8111; fax: +81-3-3356-0441. E-mail address: mshoda@hij.twmu.ac.jp

Case

Our patient was a 32-year-old man with a DILV, anatomical left-side rudimentary right ventricle, and innominate vein connecting to the right side of the superior vena cava with discordant atrioventricular (AV) and ventriculoarterial discordance following mechanical AV valve replacement. The patient underwent pulmonary artery banding and subclavian flap aortoplasty of coarctation of the aorta at 3 months of age, ventricular septation (VS) and epicardial pacemaker implantation for a surgical heart block at 4 years of age, and mechanical right-side AV valve (functional tricuspid valve) replacement at 21 years of age. Due to epicardial pacing lead failure and worsening heart failure, we attempted to place BiV transvenous pacing leads. Echocardiography prior to the BiV pacemaker implantation showed a giant right atrium with poor contraction, a left ventricular ejection fraction of 42% without contraction of the interventricular septum created by the VS, mild left-sided AV valve regurgitation, no subaortic stenosis, and no regurgitation or stenosis of the mechanical AV valve.



We cannulated the coronary sinus using a Selectra lead delivery catheter (Biotronik) and placed a quadripolar lead (Quartet model 1458Q; St. Jude Medical) into a branch of the lateral cardiac vein (Panel B). We placed a bipolar lead (QuickFlex model 1258T; St. Jude Medical) into a small anterior cardiac vein branching from the right atrium to establish BiV pacing (Panels A, B). We then implanted a BiV

pacemaker (Allure Quadra RF CRT-P PM3242; St. Jude Medical) in the left chest and programmed the BiV-VVIR mode, which resulted in stable BiV pacing. QRS duration narrowing from 194 to 158 ms, shortening of the interventricular delay from 79 to 20 ms by optimized VV delay on echocardiography, and improvement of the heart failure symptoms.

Discussion

Ventricular septation, which separates a single chamber into two functional ventricles, is a surgical alternative to the Fontan procedure for selected patients with DILV.¹ Major complications after VS include AV block and AV valve regurgitation. Transvenous lead implantation into the functional RV is impossible for DILV after mechanical AV valve replacement; rather, transvenous epicardial lead placement via the CS is required.² Nevertheless, single-site ventricular pacing may induce iatrogenic intraventricular dyssynchrony. BiV pacing is preferable; however, the open-chest approach is necessary to establish cardiac resynchronization. Here, to our knowledge, we present the first case of successful transvenous BiV pacemaker implantation in a difficult case.

Supplementary material

Supplementary material is available at *Europace* online.

Acknowledgements

We thank Dr. E. Shimada for performing the echocardiography and Dr. K. Inai for performing the outpatient follow-up.

Conflict of interest: none declared.

References

1. Margossian RE, Solowiejczyk D, Bourlon F, Apfel H, Gersony WM, Hordof AJ *et al.* Septation of the single ventricle: revisited. *J Thorac Cardiovasc Surg* 2002;**124**:442–7.
2. Sideris S, Drakopoulou M, Oikonomopoulos G, Gatzoulis K, Stavropoulos G, Limperiadis D *et al.* Left ventricular pacing through coronary sinus is feasible and safe for patients with prior tricuspid valve intervention. *Pacing Clin Electrophysiol* 2016;**39**:378–81.